



---

# Thoracic Outlet Syndrome

Discussion paper prepared for

The Workplace Safety and Insurance Appeals Tribunal

January 2000

Prepared by:

Dr. J.F.R. Fleming

Professor Emeritus, Division of Neurosurgery  
University of Toronto  
The Toronto Western Hospital

This medical discussion paper will be useful to those seeking general information. It is intended to provide a broad and general overview of a topic and is written to be understood by lay individuals. Discussion papers are not peer reviewed and do not necessarily represent the views of the Tribunal. A vice-chair or panel may consider and rely on the medical information provided in the discussion paper, but the Tribunal is not bound by the discussion paper in any particular case. It is always open to parties to an appeal to rely on or distinguish a medical discussion paper, or to challenge it with alternative evidence.

# THORACIC OUTLET SYNDROME

The term *thoracic outlet syndrome (TOS)* refers to symptoms caused by compression of nerves and/or blood vessels in the neck, in an area known as the thoracic outlet, through which the nerves and blood vessels travel to and from the arm. These symptoms may include arm pain, hand numbness, weakness and wasting of the hand muscles, and circulatory changes in the hand. The nerves that travel through the thoracic outlet are spinal nerves C-5,6,7,8 and T-1, which exit from the bony spinal column and travel together in a bundle called the *brachial plexus* to the axilla (arm pit), where they then divide into the major nerves of the arm (the ulnar, median and radial nerves). The blood vessels travelling through the thoracic outlet are the main artery and vein supplying the arm, the *subclavian artery* on its way from the aorta to the arm, and the *subclavian vein* which returns the blood from the arm to the heart.

**Anatomy of the thoracic outlet.** The thoracic outlet is located at the side or base of the neck, above the first rib, behind the clavicle, and lateral to the bony spinal column. The nerves of the brachial plexus and the subclavian artery lie between a large muscle called the scalenus anterior (which forms the front of the thoracic outlet), and another muscle called the scalenus medius (which forms the back of the thoracic outlet), and they lie just above the first rib (which forms the bottom of the thoracic outlet). The subclavian vein lies in front of the scalenus anterior muscle, which separates it from the brachial plexus and subclavian artery. Although the thoracic outlet is a relatively confined space, it normally provides ample accommodation for its contained nerves and blood vessels.

**Congenital anomalies in the thoracic outlet.** In some individuals there may be congenital anomalies in the thoracic outlet. These anomalies include: (1) the presence of an extra or cervical rib attached to the C-7 vertebra, and which may vary in length from a short rudimentary rib to an entire rib, and which tends to tent up the brachial plexus as it crosses this extra rib. (2) The presence of an abnormally long bony transverse process protruding from the C-7 vertebra, which tends to tent up the C-8 and T-1 nerves. The great majority of individuals who harbour these bony congenital anomalies have no symptoms. The brachial plexus and the subclavian artery adapt well to the particular configuration of the individual thoracic outlet. The presence of these bony anomalies in an individual with arm and hand symptoms does not necessarily mean that the anomalies are the cause of the symptoms. (3) The presence of an anomalous band of fibrous tissue in front of the brachial plexus. This fibrous band may compress the brachial plexus, and may sometimes be associated with symptoms.

**Pathological conditions in the thoracic outlet.** Whether or how much the thoracic outlet can be narrowed by swelling or overgrowth (hypertrophy) of the scalene muscles, or by swelling of adjacent ligaments or other tissues due to excessive wear and tear, repetitive awkward (e.g. overhead) movements, or by a sudden straining injury, remains speculative and controversial. The thoracic outlet may be narrowed by the presence of a tumour, such as a lung cancer involving the first rib, or by badly displaced bone fragments or excess callus formation from a fractured clavicle or a fractured first rib.

**The nerves in the thoracic outlet.** The brachial plexus consists of both motor and sensory nerves, as well as some sympathetic nerve fibres. The *motor nerves* carry impulses from the brain to activate the arm and hand muscles. *The sensory nerves* carry touch, pain, temperature, vibration sense and joint position sense information from the fingers, hand and arm to the brain. *The sympathetic nerve fibres* carry impulses from the brain and spinal cord, which can constrict blood vessels and activate sweat glands in the arm and hand. Interruption or malfunction of motor or sensory nerves may result in muscle weakness and wasting, and/or impairment of sensation in the area of skin supplied by the affected nerve. Irritation of sensory nerves may result in tingling (paraesthesia) in the area supplied by that nerve. There may be an ache or a burning pain in the area supplied by the involved nerve.

Only the lowest portion of the brachial plexus is affected by TOS. It consists of the C-8 and T-1 *spinal nerve roots*, which join together to form the lowest *trunk* and then the medial *cord* of the brachial plexus. Impaired conduction in the C-8 and T-1 nerves or the lower trunk of the brachial plexus results in weakness and wasting of the small (intrinsic) muscles of the hand, and numbness/tingling in the ring and little fingers and along the inner (ulnar) border of the palm and forearm. The extent to which the muscles are weakened and wasted, and the degree of sensory loss depends on the degree to which the nerves are impaired.

**Classification of TOS.** "TOS is not the name of a single entity, but rather a collective title for a number of conditions of variable validity" (*Wilbourn p.130 Muscle and Nerve Jan 99*). When the signs and symptoms of TOS are due to compression of the brachial plexus nerves, the condition may be designated as *neurogenic TOS* (as opposed to *vascular TOS*). It is conceivable that a minimal degree of compression, or even "irritation" of the nerve fibres of the brachial plexus in the thoracic outlet, insufficient to cause any motor or sensory loss, might cause an ache, pain or discomfort in the arm, with or without a subjective feeling of tingling in the ring and little fingers. Thus, some authors have subdivided neurogenic TOS into "*true neurogenic TOS*", in which there is objective evidence of neurological

abnormalities, and "*non-specific* or "*disputed neurogenic TOS*", in which there are no objective abnormal neurological findings. Disorders under the designation of "true neurogenic TOS" are universally accepted by the medical community; they occur very rarely, and have characteristic clinical pictures. "Non-specific or disputed TOS" is contentious; its proponents consider it to be very common, while skeptics believe that if it exists at all, it is exceedingly uncommon.

*Vascular TOS*, with symptoms due to involvement of the subclavian artery, is extremely rare, and does not play a part in producing the symptoms of neurogenic TOS. Traditionally it has been believed that the subclavian artery may be compressed in the thoracic outlet in certain individuals when the shoulder and arm are being used a lot, and the thoracic outlet is presumed to become tighter due to this excess activity. In a few other individuals, the thoracic outlet was presumed to be excessively tight even at rest. Various so-called "thoracic outlet compression tests"\* have been interpreted as confirming the presence of TOS. However, these tests are "positive" in as many as 50% of normal people, and are no longer considered reliable or valid in the diagnosis of TOS.

It should be remembered that the flow of blood in any large artery is proportional to the fourth power of the diameter of that vessel. In other words, an extremely severe degree of narrowing of the subclavian artery would be required to cause a significant decrease in the amount of blood flowing to the arm and hand. In order to narrow the artery so severely, a marked degree of compression of the thoracic outlet would be required, and would also compress the brachial plexus so much that the patient would be seeking medical attention with obvious signs of neurogenic TOS long before signs of impaired circulation develop. Severe subclavian artery compression usually only occurs when a bony abnormality such as a cervical rib is present. When severely compressed, the artery dilates distal (downstream) to the point of compression ("post-stenotic dilatation"). This dilatation predisposes to the deposition of thrombi (blood clots) inside the artery, and these clots may break off (emboli), travel down the artery and block the small arteries in the hand and fingers, causing ischemic changes such as necrosis or gangrene.

---

\*obliteration of the radial artery pulse at the wrist when the arm is abducted and the shoulder is externally rotated (Adson test), or the reproduction of the patient's symptoms when the arm is hyperabducted or when the shoulders are braced in the military position, or during the Elevated Arm Stress Test (EAST test).

**Venous.** Obstruction of the subclavian vein is exceedingly rare. The subclavian vein may become blocked by a thrombus (blood clot) after unusual and prolonged exertion ("effort thrombosis"), leading to a very swollen, tender, congested limb. This is not part of the thoracic outlet syndrome. Minor degrees of subclavian vein compression do not cause any symptoms.

### Clinical Picture

**True Neurogenic TOS.** In true neurogenic TOS, there is *weakness and wasting of the small muscles of the hand* (the intrinsic hand muscles), especially those muscles in the palm near the base of the thumb (thenar muscles), but also those on the inner side of the palm (hypothenar muscles) and those within the hand between the metacarpal bones (interosseous muscles). There is often an *intermittent aching* along the inner (medial) aspect of the forearm and hand, with *paraesthesiae (tingling, numbness)* and decreased sensitivity to touch and pin prick testing in this area. The ache and paraesthesia may be exaggerated by certain limb positions such as carrying a heavy object in the hand. The tendon reflexes in the arm (biceps, triceps and brachio-radialis) remain normal, as the nerves supplying these reflexes are located in the mid and upper portions of the brachial plexus, and are not affected by TOS.

**Non-specific Neurogenic TOS.** In non-specific or disputed neurogenic TOS, there are no abnormal motor findings (i.e. no true muscle weakness or wasting), and no sensory findings (i.e. no decreased sensitivity to testing with touch or pin prick). If muscle weakness is reported, it is usually described as "subjective" or "voluntary" or "release weakness", but there is no muscle wasting, nor is there electro-diagnostic evidence of muscle denervation. The predominant complaints are pain and sometimes tingling and numbness (paresthesiae), often in a rather diffuse and non-specific distribution in the shoulder, arm, forearm and hand. These symptoms are sometimes worse with activity or when carrying a heavy object in the hand, and sometimes persist at rest. Sometimes it is claimed that manoeuvres that are presumed to tighten the thoracic outlet, such as arm hyperabduction, the "elevated arm stress test" (EAST test) or the Adson test will reproduce or aggravate the pain and/or paresthesiae. In non-specific TOS, there may also be a variety of symptoms that are completely unrelated to the thoracic outlet, such as headaches.

It is now known that compression of the subclavian artery does not play a significant role in neurogenic TOS, and hence tests designed to detect subtle degrees of decreased blood flow to the hand (doppler, finger plethysmography) or manoeuvres to attempt to reproduce the patient's symptoms by compressing the subclavian artery, are no longer considered to be valid or reliable in the diagnosis of neurogenic TOS.

Tenderness on pressing over the thoracic outlet above the clavicle, production of pain or numbness in the arm and hand with supra-clavicular pressure, or tingling in the hand or fingers on tapping over the brachial plexus in this region have not been shown to have any consistent reliability or validity in the diagnosis of TOS.

### Differential Diagnosis

**Other conditions that may be mistaken for TOS.** Weakness and wasting of hand muscles, sensory loss in fingers, tingling and numbness in the fingers, and aches and pains in the arm, forearm and hand may be caused by a variety of neurological disorders. Of these, carpal tunnel syndrome (CTS) is the most common. Carpal tunnel syndrome may co-exist with TOS, but is not a part of TOS. (The controversial issue of "double crush syndrome" is considered at the end of this paper). Other conditions that must be considered in the differential diagnosis of neurogenic TOS include ulnar nerve entrapment at the elbow (cubital tunnel syndrome) or in the hand in Guyon's canal\*, and other peripheral nerve disorders in the arm. Cervical nerve root compression (cervical radiculopathy) or cervical spinal cord disorders such as syringomyelia may also present with symptoms somewhat similar to those of neurogenic TOS. It is essential to be certain that these conditions have been considered and excluded, usually by careful history taking and analysis of the symptoms, together with a detailed neurological examination. It may also be necessary to obtain electro-diagnostic studies and/or appropriate imaging of the cervical spine by x-rays, C.T. scan or M.R.I. to rule out some of these conditions.

---

\*Guyon's canal: the tunnel at the base of the hand, just below the wrist, through which the ulnar nerve travels

Musculo-skeletal disorders in the arm, such as rotator cuff injury, tendonitis, bursitis, fibrositis and others, have to be considered as possible causes of arm pain. Careful history taking and physical examination should readily distinguish these conditions from true neurogenic TOS, but they may easily be mistaken for non-specific TOS.

A variety of vascular conditions must be considered and ruled out before the diagnosis of vascular TOS can be made. These include vasospastic disorders, with inappropriate constriction of blood vessels, such as Raynaud's phenomenon, reflex sympathetic dystrophy, collagen vascular disease and arteritis.

### Diagnostic Tests

**There is no single laboratory test that can confirm the diagnosis of TOS. The diagnosis must be based on a combination of the patient's symptoms, the findings on physical and neurological examination, plus appropriate laboratory tests.**

**Electro-diagnostic tests: Nerve Conduction Studies (NCV), Electromyography (EMG), F-Waves and Somato-Sensory Evoked Potentials (SEP).** In true neurogenic TOS, there is usually decreased amplitude in the sensory and motor nerve action potentials in portions of the ulnar and median nerves, and also there is EMG evidence of denervation of hand muscles. It is not technically possible to measure nerve conduction across the brachial plexus because of its deep location in the neck. However, F-wave measurement is a technique that attempts to measure conduction across the plexus, by sending impulses anti-dromically (backwards) *up* the motor nerves and across the plexus; in true neurogenic TOS, the F-wave may show slowed conduction, but there is usually already sufficient clinical and EMG evidence to support the diagnosis, making this test superfluous. In non-specific TOS, there are no consistent or reliable electro-diagnostic abnormalities. Of course, electro-diagnostic tests are essential in ruling out other neurologic abnormalities in the arm, such as CTS or ulnar nerve entrapment.

Somato-sensory evoked potentials (SEP) are measured by scalp electrodes when an electrical stimulus is applied to the skin over a nerve in the arm. SEP show delayed conduction or decreased amplitude when there is already clinical, NCV and EMG confirmation of true neurogenic TOS. SEP findings in non-specific neurogenic TOS have been inconsistent, and have not been shown to be reliable.

**Imaging.** Plain *cervical spine x-rays* and *chest x-ray* are useful in demonstrating the presence of a cervical rib or an unusually long C-7 bony transverse process, and also help to rule out a destructive tumor involving the first rib or other surprise pathology. *CT scan* and *M.R.I. of the thoracic outlet* have not been shown to have benefit in evaluating the size or shape of the thoracic outlet, nor the ability to consistently show the presence of a constricting fibrous band. *CT and M.R.I of the cervical spine* are helpful in evaluating the cervical spinal column and its contained nerve roots and spinal cord, where a potential lesion that is causing symptoms mimicking TOS might be found. *Arterial doppler flow studies* and *plethysmographic studies* have been advocated in the past by those who believed that TOS is due to compromise of the subclavian artery as well as the brachial plexus; as noted above, most experts today find these tests of little value.

*Arteriography* (injection of radio-contrast material directly into the artery and then taking x-rays) is important in the diagnosis of vascular TOS as it clearly visualizes the condition of the subclavian artery. In the past, arteriography has been used in an attempt to demonstrate if narrowing of the artery at the thoracic outlet occurs when the arm is placed in hyperabduction. However, it is an invasive tests, and unnecessary in true neurogenic TOS, which can be diagnosed by simpler means. *Venography* (the injection of radio-contrast material into an arm vein, followed by x-rays) is only of value in the diagnosis of the very rare condition "effort thrombosis" of the subclavian vein, and not in the diagnosis of TOS. In the past, attempts were made to establish a diagnosis of TOS by performing venography with the arm placed in hyperabduction; constriction of the vein with the arm held in this position was presumed to indicate a narrow thoracic outlet and therefore confirm the diagnosis of TOS. However there is no reliable evidence to support this theory, and venography is no longer considered to be of any value in the diagnosis of TOS. The role of arteriography and venography in non-specific or disputed TOS is unproven, and their use in this context is probably unjustified.

## Management

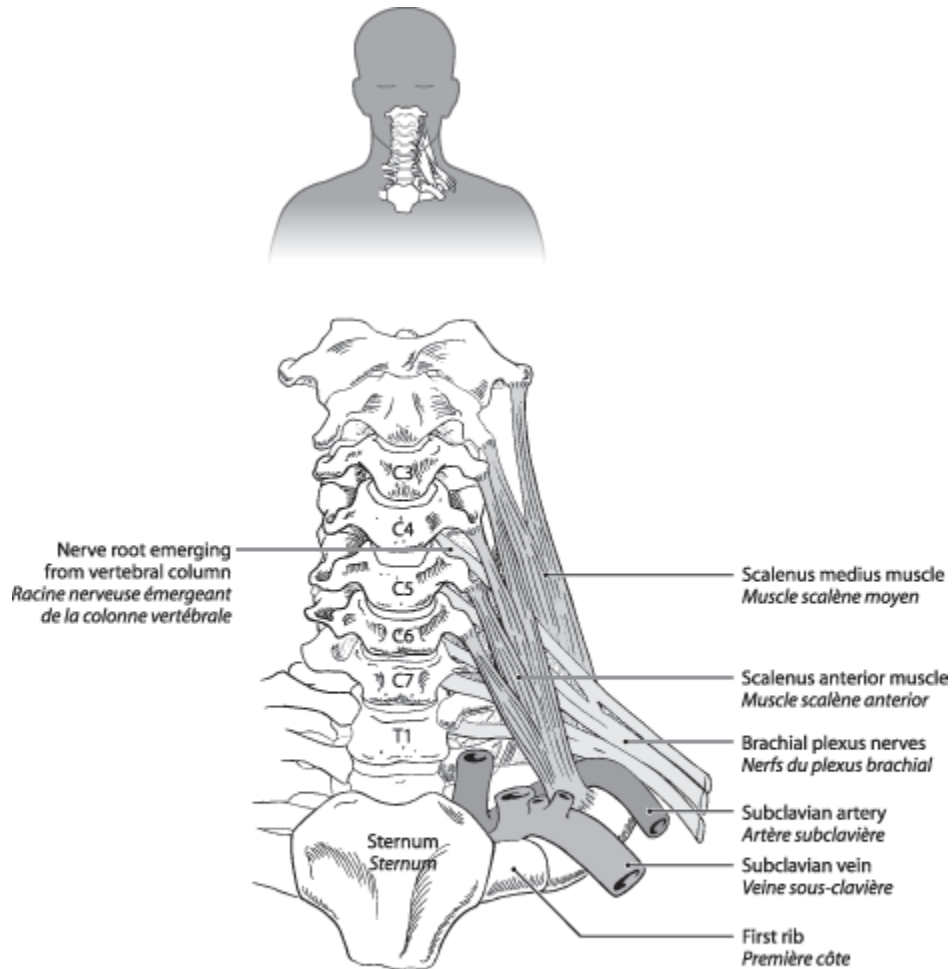
*Neurogenic TOS*, with wasting and weakness of hand muscles and/or sensory loss and/or severe pain, usually requires surgical treatment. *Vascular TOS*, with evidence of impaired circulation in the arm or hand, also requires surgery. In *non-specific or disputed TOS*, the very existence any organic basis in the thoracic outlet is unproven, and there is no reliable evidence to support a role for surgery for this condition.

## Thoracic Outlet Syndrome

---

Decompression of the brachial plexus in the thoracic outlet may be accomplished by a variety of surgical approaches. Removal of the first rib by approaching it through the axilla has been very popular in the past. However it is a major operation, and has a significantly high rate of complications, including damage to the brachial plexus, as well as a high incidence of failure to relieve symptoms. First rib removal is being performed much less often nowadays, as it is being recognized that the brachial plexus can be much better visualized and decompressed by a direct anterior neck approach, through which compressing fibrous bands or muscles can be directly seen and divided. The first rib itself probably does not contribute to brachial plexus compression, nor compromise the lower part of the plexus which happens to travel over it. Cervical ribs are removed by the anterior neck approach.

The results of surgery for true neurologic TOS are generally good; the progression of muscle wasting and sensory loss is usually halted, and pain is usually relieved. The results of surgery for non-specific or disputed TOS are mixed, and quite often unfavorable, probably because different surgeons have different views on what does or what does not constitute TOS, and there are no clear diagnostic criteria or standards for this condition. Therefore patients in this category undergoing surgery represent a mixed group with a variety of pathologies, or possibly even no organic pathology, and good clinical studies of the surgical results cannot be done. Conservative management is preferable for non-specific or disputed TOS, except in extremely rare situations.



**Figure 1. Front view of neck showing brachial plexus traveling between scalene muscles and over first rib**  
**Figure 1. Vue de face de la région du cou montrant le plexus brachial passant entre les muscles scalènes et au-dessus de la première côte**

### Bibliography

Dawson DM, Hallet M and Wilbourn AJ: Entrapment Neuropathies, 3rd edition. Lippincott - Raven, Philadelphia, 1999. Chapter 8, pages 227 - 250

Kline DG and Hudson AR. Nerve Injuries, Operative Results for Major Nerve Injuries, Entrapments and Tumors, WB Saunders Company, 1995. Chapter 17, pages 473 - 493.

Leffert RD: Chapter 52 in Omer GE, Spinner M and Van Beek AI: Management of Peripheral Nerve Problems, 2nd edition, WB Saunders Company, 1998, pages 494 - 500.

Roos DB: Thoracic Outlet Syndrome is Underdiagnosed. Muscle and Nerve, January 1999, pages 126 - 129.

Wilbourn AJ: Thoracic Outlet Syndrome is Overdiagnosed. Muscle and Nerve, January 1999 pages 130 - 138.

Wilbourn AJ: Thoracic Outlet Syndromes. Neurological Clinics, Volume 17, August 1999, pages 477 - 497.